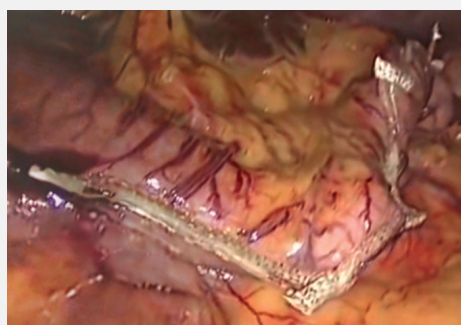


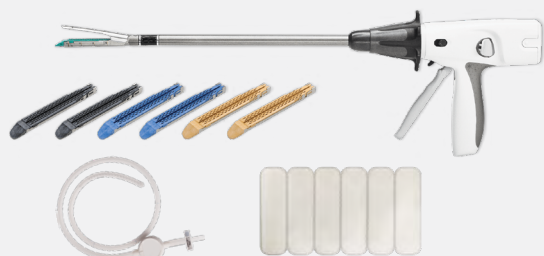THE RIGHT LINE EVERY TIME

Achieving a more consistent surgical sleeve anatomy is possible with the newest technology for sleeve gastrectomy.

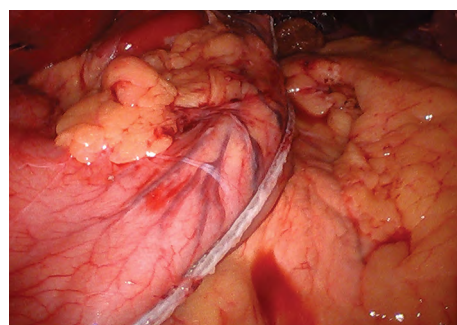
Freehand Sleeve Gastrectomy



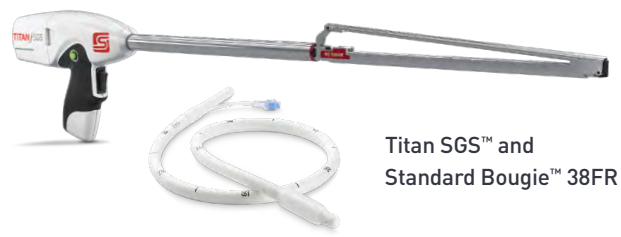Freehand Sleeve Equipment Technology



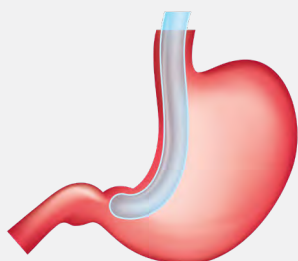
Standard Sleeve® Anatomy-Based Sleeve Gastrectomy



Standard Sleeve Equipment Technology

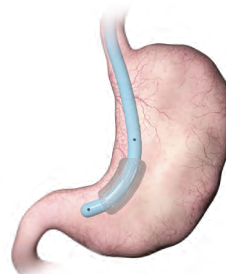


Titan SGS™ and
Standard Bougie™ 38FR



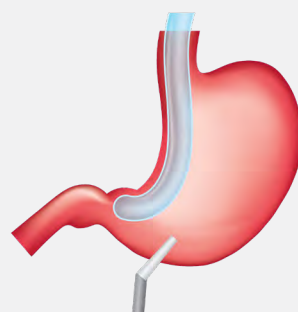
INSERT BOUGIE

A 36Fr–40Fr bougie serves as a template sizer.



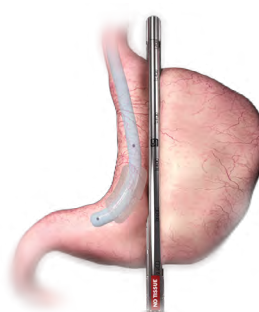
INSERT BOUGIE

With its key anatomical landmarks, the Standard Bougie 38FR serves as a guide for precise alignment of the Titan SGS while also protecting the incisura angularis.



INSERT STAPLER

Starting 4 to 6cm from the pylorus and using the bougie as a guide, a short stapler is used to divide the stomach one cartridge at a time.



INSERT STAPLER

The entire stomach tissue can be placed into the Titan SGS. By placing the stapler approximately 1cm from the GE junction, 3cm from the incisura angularis and 4 to 6cm from the pylorus, the surgeon can visualize the full staple cut line in a single plane.

TITAN SGS™ EXCLUSIVELY FOR BARIATRIC SURGEONS

Freehand Sleeve Gastrectomy

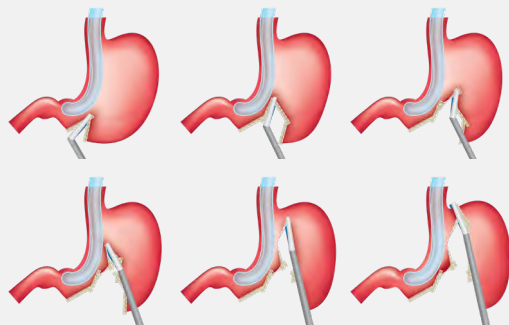
Standard Sleeve™ Anatomy-Based Sleeve Gastrectomy

DIVIDE STOMACH

On average, it takes between 5 to 7 staple cartridge firings to complete the sleeve pouch anatomy.



12–15 minutes

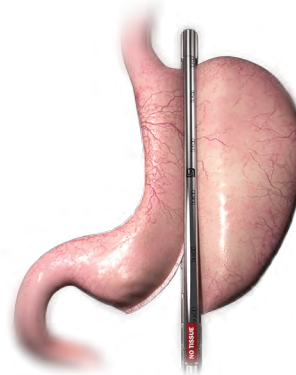


DIVIDE STOMACH

Titan SGS fires a single cartridge, completing the stapling in approximately 55 seconds.

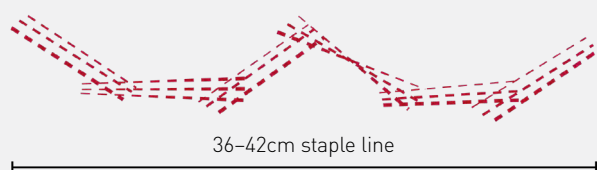


< 60 seconds



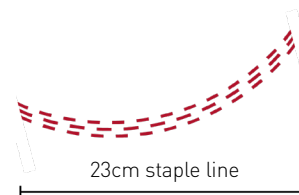
INSPECT STAPLE LINE

This approach can be highly variable when attempting to place multiple staple cartridge firings into floppy, stretchy, two-sided stomach tissue. Results can create inconsistencies across the entire length of the staple line when using tools not specifically designed for the procedure.



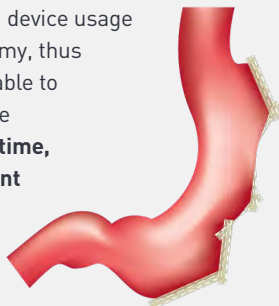INSPECT STAPLE LINE

A single Titan SGS firing forms a seamless, consistent and continuous staple line the entire length of the stomach. This can reduce the chances of malformed staples due to crossing previous staple lines and staple line spiral which can lead to obstruction. It may also result in less bleeding and improved strength of the staple line.¹



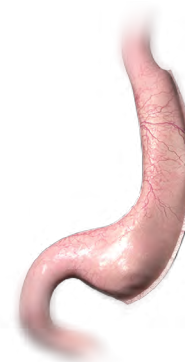ACHIEVE NEW ANATOMY

Highly variable techniques and device usage yield inconsistent pouch anatomy, thus bariatric surgeons have been able to achieve the ideal tubular sleeve anatomy **less than 40% of the time, resulting in inconsistent patient outcomes including GERD² and nausea.**



ACHIEVE NEW ANATOMY

The ideal tubular surgical sleeve anatomy is a consistent shape that is free of overlapping staple lines, kinks, twists or spirals. **Potential improvement in resolution of GERD and nausea.³**



¹ Salyer, Spuzillo, Wakefield, et al. Assessment of a novel stapler performance for laparoscopic sleeve gastrectomy. 2020.

² Toro, JP, et al. Association of radiographic morphology with early gastroesophageal reflux disease and satiety control after sleeve gastrectomy. *Journal of American College of Surgeons*. Sep; 219(3):430-8. 2014.

³ Thompson, Dhar, Hanseman, et al. Anatomy-Based Sleeve Gastrectomy Is Associated With Lower GERD Versus Sleeve Gastrectomy with Bougie. American College of Surgeons Quality and Safety Conference. Washington DC. July 2019.